A CYTOLOGICAL AND CYTOCHEMICAL STUDY OF THE MALE ACCESSORY REPRODUCTIVE GLANDS IN THE JAPANESE BEETLE, POPILLIA JAPONICA NEWMAN

JOHN MAXWELL ANDERSON

Arnold Biological Laboratory, Brown University

Introduction

These studies were undertaken in order to investigate the cytological details of the accessory reproductive glands of Popillia, and to determine whether regional cytological differences could be correlated with differences in secretory activity. Some of the techniques of cytochemistry have been applied to these glands to elucidate the general nature of the secretion product, and to localize sites of origin of its components.

The male genital system of insects is typically characterized by the presence of a varying number of accessory glands appended to the principal effluent passages. These have been variously considered as analogous to Cowper's gland and the prostate of vertebrates (Hegetschweiler, 1820) and as seminal vesicles (Dufour, 1824). Escherich (1894) correctly described the functions and embryonic origins of the accessory glands of several Coleoptera. Those of Lucanus (a Scarabaeoid beetle related to Popillia) were shown to be of mesodermal origin. Escherich had demonstrated (1893) the similarities between the male genital tract of Lucanus and those of the Scarabaeidae. The conclusions of Escherich were substantiated by Blatter (1897) in a histological study of the accessory glands of Hydrophilus. Comparative studies of the male genital system in a large number of Coleoptera by Bordas (1900) elucidated the features of this system with its accessories and described the characteristic appearance of the accessory gland secretions. Studies by Rittershaus (1927) of the structure and biology of Anomala and Phyllopertha dealt briefly with the structure and function of the accessory glands of the male. The glands of these species, which are members of the same family (Rutelidae) as Popillia closely resemble those of Popillia. In these beetles the secretion product of the accessory glands serves as a vehicle for sperm transfer and coagulates in the female tract to form spermatophores.

Material and Methods

The entire reproductive tract was dissected from adult male Japanese beetles. The glands were carefully teased from their positions along the gut wall and allowed to fall into loose coils about the testicular masses. The systems thus removed were fixed and subsequently treated in a variety of ways, depending upon the particular structures or substances to be demonstrated. The specific techniques used will be summarized below in connection with the observations.

It is disadvantageous to handle the material as entire reproductive tracts because the coils of the gland become disposed at random about the remainder of the organs. Since in many of the techniques used it is advisable to employ adjacent slides as controls, it often happens that control and test slides contain sections of different regions of the gland. As a result, some levels have eluded treatment with some of the techniques. Indications will be given below of regions for which specific data are lacking.

Observations

A. General morphological considerations

Gross anatomy and relationships. There are two accessory reproductive glands in the adult male. They are long, coiled tubes which lie closely applied to the wall of the gut. Their length is approximately 4 times that of the abdomen, although, since they are extremely delicate, it is difficult to extend them fully. In the living animal the glands are a yellowish color. The small apical portion (diameter about 65 μ) tapers gradually to an expanded region (diameter about 246 μ) at the basal portion of the gland. The expanded sac-like structures continue posteriorly to the point at which the two glands join to receive the vasa deferentia and form the ejaculatory duct.

Microscopic anatomy. The following observations were made on material fixed in Flemming's strong solution, sectioned serially at 5 μ, and stained in iron-alum hematoxylin. Other glands fixed in Zenker-acetic were sectioned serially and stained with eosin-Y and methylene blue.

At its apical end, designated as Level I, each gland consists of an almost solid cylinder of moderately tall columnar cells 24 μ high and about 9 μ broad (Figs. 1, 16). Arranged radially, the cells rest upon a very thin basement membrane, and they bound a small, irregular lumen. In the lumen, a scanty, thin secretion lies upon the free ends of the cells. Each cell contains a large, ovoid nucleus near its basal end.

A short distance posteriorly, the diameter of the gland increases gradually to about 98 μ. The cells at this level (referred to as Level II) are of the same shape and size as those in Level I, but the diameter of the lumen has increased to approximately 60 μ (Fig. 7). The secretion in the lumen appears to differ little from that in Level I, but it is more abundant and contains numerous scattered small globules present in small numbers at Level I. The separation of the upper region of the gland into Levels I and II is largely a matter of convenience, based chiefly on differences in diameter.

About midway between the apex and the enlarged basal portion of the gland, the diameter increases to 158 μ and the lumen measures approximately 88 μ (Level III). The cells are much taller than those in the upper regions (Figs. 3, 22), measuring about 46 by 10 μ. Most of them appear to be carrying on intense secretory activity. That the secretory process is of the apocrine type is indicated by globules of secretion-packed cytoplasm which are budded or pinched off from the apices into the lumen. Levels II and III are united by a short intermediate zone in which Level II gradually blends into Level III (Fig. 8).

At this zone of transition two layers of striated muscle are found, for the first time, outside the basement membrane. The outer layer consists of narrow, separate,

parallel bands of longitudinal fibers; the inner, of an uninterrupted sheet of circular muscle. The total thickness of the muscle coats is 3 to 5 μ.

The accumulation of secretion in the lower regions of the gland lumen proceeds rapidly and exerts a marked influence upon the histology of the portion nearer the basal end. The increase in total diameter of the gland as it approaches the ejaculatory duct is accompanied by an increase in the diameter of the lumen and a decrease in the height of the epithelial cells. In the largest region of the gland (Level IV) the total diameter approximates 250 μ; the diameter of the lumen is 225 μ; the muscle coats remain 3 to 5 μ thick. The epithelial cells are cuboidal or squamous and measure about 10 μ in height. There is a gradual transition from Level III to Level IV. There is practically no evidence of secretory activity in cells typical of Level IV.

B. Special methods and observations

Cytoplasmic basophilia. Serial sections of material fixed in Zenker-acetic were stained with eosin-methylene blue. Adjacent sections were treated with ribonuclease [1] before staining.

The cells of all the levels of the gland show intense cytoplasmic basophilia. In Levels I and II, the cells have a dense perinuclear basophilic area from which radiate undulant basophilic strands. These fiber-like elements lie parallel to the longitudinal axis of the cell and pass around clear cytoplasmic areas above and below the nucleus (Fig. 10). The free secretion in the lumen consists of a uniformly acidophilic, granular mass of ground substance. In Level I it contains a few small, clear, unstained globules or vacuoles which are more numerous in Level II. Occasionally some parts of the ground-mass may stain with methylene blue, giving rise to a purplish rather than a blue tint (Fig. 7, edges of secretion mass).

The cells in Level III also show a perinuclear concentration of basophilia from which basophilic strands radiate toward the apices of the cells (Figs. 3, 8). The secretion droplets which are being shed from the apices of these cells are intensely and solidly basophilic. However, as these cytoplasmic globules break down and become parts of the free secretion mass their contents stain less intensely. The free secretion from this level down consists of an acidophilic granular ground substance which contains scattered clear globules (these two apparently produced in Levels I and II), and numerous somewhat basophilic larger elements produced in Level III.

The cells in the largest region of the gland show none of the streaming basophilic fibrillar structures characteristic of other levels. In these cells (Level IV), the nucleus is capped proximally and distally by strongly basophilic masses (Figs. 3, 4, 5). These cells show no evidence of secretory activity.

After treatment with ribonuclease all traces of cytoplasmic basophilia are removed. The strands or fibers remain as pale, acidophilic "ghosts" in the cytoplasm, although no remnants of the perinuclear concentrations persist (Figs. 2, 6, 11). The basophilic elements free in the lumen, however, are not affected by the enzyme (Figs. 4, 6).

Nuclear basophilia is virtually unchanged by ribonuclease, with the exception of the two or more large, conspicuous nucleoli which become partially acidophilic;

[1] Supplied by Dr. William Montagna of this laboratory.

these give the impression of a basophilic shell which encloses an inner acidophilic mass (cf. nucleoli in Figs. 5, 6). In untreated control sections the nucleoli are deeply basophilic.

Glycogen and other polysaccharides. Material fixed in cold Rossman's fluid and sectioned serially at 5 μ was treated according to the technique of Hotchkiss (1948). Sections exposed to saliva to digest glycogen were processed simultaneously as controls, and for the demonstration of polysaccharides other than glycogen.

Aggregations of Schiff-positive granules appear in the cells of all levels of the gland. In Levels I and II these masses lie both below and above the nucleus and extend partway from the nuclear membrane toward the apex of the cell. These aggregations evidently occupy the spaces between the basophilic strands described above, and they are more numerous in Level I than in Level II. These elements give a rather weak color reaction when compared with that in the glycogen-rich cells of the neighboring fat-body. The granular secretion in the lumen also gives a weak, pink reaction with leucofuchsin, but the small clear droplets are negative.

At Level III the tall apocrine cells show aggregates of pink granules at their free ends, and only a few near the nucleus. The granules are particularly concentrated in the terminal protoplasmic processes, and these small masses appear to recolorize the Schiff reagent more thoroughly as they break down and become the larger bodies in the free secretion. These bodies, which correspond to the basophilic components noted in eosin-methylene blue preparations, stain a deep magenta with leucofuchsin. (Fig. 9).

Plate I

All figures are of paraffin-embedded material sectioned at 5 μ. Magnifications given are of the figures as they appear here.

Figure 1. Basophilia, Level I, eosin-methylene blue. Note cytoplasmic strands streaming from juxtanuclear concentrations; nucleoli. 750 ×.

Figure 2. Basophilia, Level I, eosin-methylene blue after ribonuclease digestion. Note persistence of basophilia in rims of nucleoli; acidophilic "ghosts" of cytoplasmic strands. 750 ×.

Figure 3. Basophilia, Level III (upper), Level IV (lower); eosin-methylene blue. Note deep basophilia in protoplasmic processes of Level III cells; basophilic elements in free secretion. 750 ×.

Figure 4. Basophilia, Level IV, eosin-methylene blue. Note basophilic areas surrounding nuclear caps; basophilic secretion bodies. 330 ×.

Figure 5. Same cells shown in Figure 4. 750 ×.

Figure 6. Basophilia, Level IV, eosin-methylene blue after ribonuclease digestion. Note disappearance of nuclear caps; persistence of basophilic rims of nucleoli and of basophilic elements in free secretion mass. 330 ×.

Figure 7. Basophilia, Level II. 330 ×.

Figure 8. Basophilia, transition zone Level II–III. Note first appearance of basophilic bodies in secretion mass.

Figure 9. Periodic-acid-Schiff reaction, Level IV. Note glycogen bodies in cells; deeply-stained mucus flocs in secretion. Dark mass at upper left corner is glycogen in adjacent fat-body cells. 750 ×.

Figure 10. Basophilia, Level I–II; as in Figure 1. Note clear cytoplasmic areas. 330 ×.

Figure 11. Basophilia, Level I, after ribonuclease digestion. Same section as in Figure 2. 330 ×.

Figure 12. Toluidine blue reaction, Level IV. Note metachromatic flocs in secretion; ground-mass of secretion is greenish. 330 ×.

PLATE I

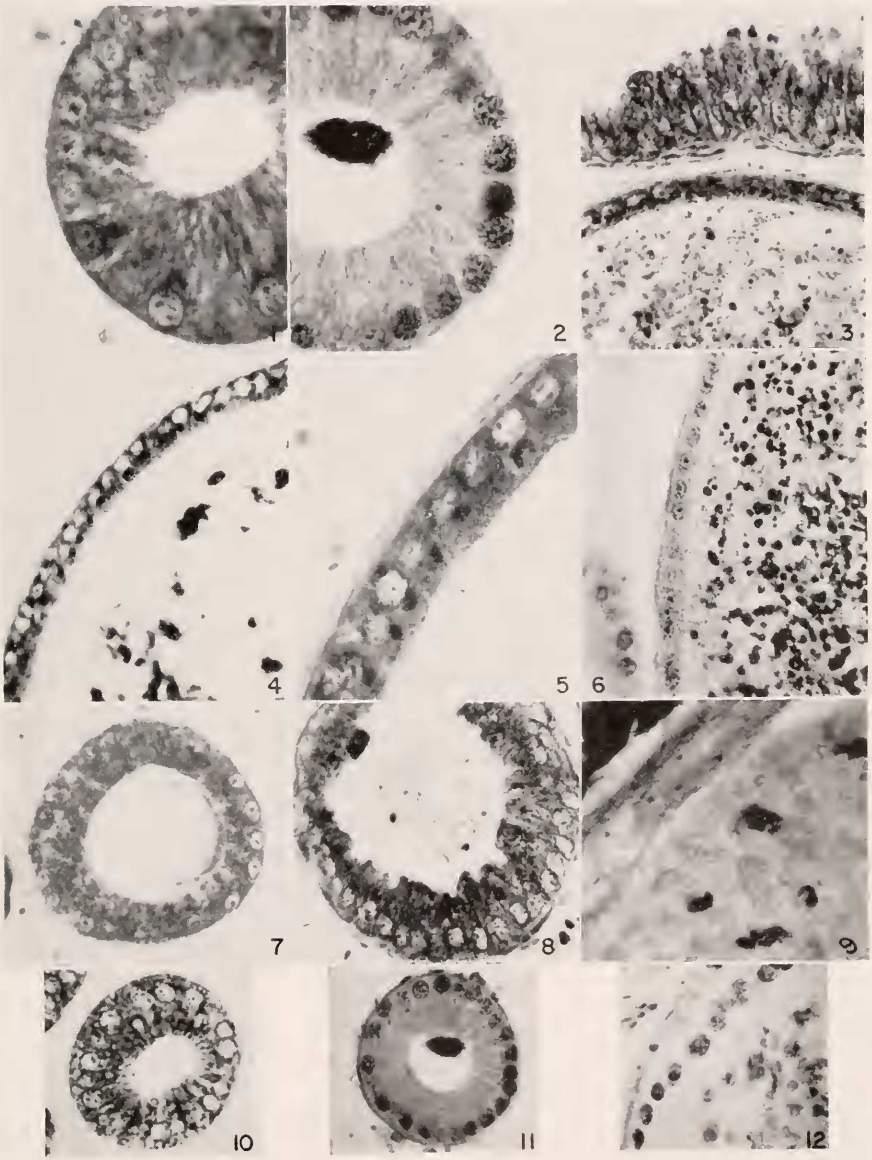

At the largest level of the gland the cuboidal cells contain few granules comparable with those in upper levels. Each cell shows, near its nucleus, a few moderate-sized masses which stain intensely, and a few smaller granules near the free border which stain less deeply (Fig. 9). The free secretion at this level does not differ from that seen at Level III.

Except for the moderate-sized masses in cells at Level IV, none of the elements described above is destroyed by salivary digestion prior to treatment with the Schiff reagent. The appearance of the secretion within the lumen is not visibly affected by salivary amylase.

Metachromatic substances. For the demonstration of metachromasia, material was fixed in basic lead acetate-formaldehyde, sectioned serially at 5 μ, and stained in 0.1 per cent toluidine blue in 1 per cent alcohol; these sections were dehydrated and washed in 95 per cent and absolute alcohol, and mounted in balsam. Parallel series were stained in alcoholic toluidine blue at pH 3.8 and in a similar solution of the stain buffered to pH 5.0. Control sections were incubated for 6 hours with hyaluronidase as recommended by Wislocki, Bunting, and Dempsey (1947) and then stained with toluidine blue as above.

In sections stained at pH 5.0, the secretion in the lumen remains unstained, and the cytoplasm of the cells at all levels shows a general faint metachromasia. This non-localized and apparently non-specific metachromasia is probably of no significance. In unbuffered solutions of toluidine blue at pH 3.8, the cytoplasm of the gland cells is basophilic, while the large bodies scattered in the free secretion at Level III and below (which, it will be recalled, are highly Schiff-positive) are strongly metachromatic (Fig. 12). The ground substance of the secretion mass stains a bright greenish-blue. The granules in the cytoplasm of the gland cells are not metachromatic; if they do stain green, like the ground-mass in the lumen, this color is masked by the basophilia of the surrounding cytoplasm.

Treatment with hyaluronidase has no observable effect on the metachromatic staining of these substances with toluidine blue.

Lipids. Several methods were used to demonstrate lipoid sustances in the accessory glands.

1. Sudan black: thin frozen sections of material fixed in calcium-formaldehyde and embedded in gelatin were treated with sudan black according to Baker's (1944) directions. Such treatment reveals, at all levels, a variety of discrete cytoplasmic elements. At Level I, dot-like and irregularly-shaped bodies lie scattered in the cytoplasm and gathered at the basal ends of the nuclei. Many of these blackened structures are of different sizes and form irregular rims about clear vacuoles (Fig. 13). In the cells in Level II the vacuoles are larger and generally more numerous, lying between the nucleus and the free border of each cell. At Level III (Fig. 14) these bodies are similar to those in Level II in distribution and quantity, and it is apparent that no sudanophilic elements are concentrated in the protoplasmic processes, although some vacuolate bodies lie near the free ends of the cells. In the lower regions of the gland the appearance of the blackened structures is similar to that in upper levels, but they are fewer in number and lie chiefly near the nuclei. Reaction of the free secretion in the lumen to sudan black treatment in-

dicates that small amounts of lipoid material are present at all levels; the secretion mass shows scattered small droplets of sudanophilic substance lying dispersed in the ground-mass. In Level II, rows of small blackened droplets appear just outside the free borders of the cells, indicating that Level II is probably the chief site of release of the lipoid elements in the secretion. However, lipoid droplets are present in the lumen at Level I also. These small sudanophilic droplets apparently correspond to the small clear globules which remain unstained by eosin-methylene blue and by the Schiff reagent.

2. Sudan black following postchromation: material fixed in calcium-formaldehyde was treated with dichromate-calcium before embedded in gelatin, sectioned on the freezing microtome, and colored with sudan black and carmalum (Cain, 1947a).

This manipulation reveals much additional lipoid material in the gland cells. The cells near the apex of the gland contain massive clumps of sudanophilic material which occupy almost the entire volume of the cytoplasm, above and below the nucleus (Fig. 16). Cells in Level II are similarly rich in sudanophilic elements, but these become less numerous and more scattered in the cytoplasm at the transition zone between Levels II and III. In this zone, and in Level III, the majority of the sudanophilic elements are clearly vacuolated, and they lie chiefly in clumps above and below the nucleus (Figs. 17, 18). Level IV cells show small clumps of blackened vacuolated bodies near their nuclei.

The free secretion is more sudanophilic after postchromation; many additional small to moderate-sized lipid droplets, some in Level I but more numerous in Level II and below, are revealed (Figs. 16–18).

3. Acid hematein routine: phospholipines were demonstrated by Baker's (1946) acid hematein test. This technique gives results essentially similar to those obtained by the use of Cain's postchromed-sudan black method, except that in the cells below Level II fewer cytoplasmic structures are colored. The crowded clumps previously noted in cells at Level I and upper Level II stain a deep blue to blue-black with acid hematein (Fig. 15). Unfortunately, only sections of the upper and lower transition zones of Level III have been found in these preparations; in the former, scattered vacuolated structures showing some concentration toward the nucleus are in evidence. Near the beginning of Level IV, the cells show positively-staining perinuclear elements which extend toward the free border (Fig. 21). Cells typical of Level IV present, very clearly, concentrated small globular aggregates at the upper ends of their nuclei, and some globules below the nuclei.

The free secretion shows some small, blue-black globules at all levels; these are more numerous below Level I. Some of the larger elements of the secretion stain sporadically a dark blue, the ground-mass, generally brown to yellow (negative), and the remaining large hyaline areas (Fig. 21) do not stain at all.

4. Acid hematein following pyridine extraction: this is the control procedure for the acid hematein test for phospholipine (Baker, 1946). In the accessory reproductive glands, none of the cytoplasmic acid hematein-positive elements are present after the application of the pyridine extraction test (cf. Fig. 19 with 15, 22 with 21). This, according to Baker (1946) and Cain (1947 b), identifies the cytoplasmic acid hematein-positive substances as phospholipine. It may thus be

concluded that all cytoplasmic bodies stained by acid hematein in this material contain phospholipine.

Comparison of the reaction of the free secretion to acid hematein before and after pyridine extraction reveals that some, but not all, of the reactivity of the globules is removed by the action of the solvent (cf. secretion mass, Figs. 21 and 22). This substantiates the result of treatment with sudan black, which showed that some lipid was present in the secretion product; the acid hematein test further demonstrates that at least some of the lipid in the secretion consists of phospholipine. Since considerable amounts of residual secretion stain with acid hematein even after exposure to pyridine, particularly in the moderate to large bodies, this bears out the other evidence that some of it is non-lipoid.

5. Osmication techniques: treatment of this material with such techniques as that of Worley (1946) reveals vacuolar and dot-like structures within the gland cells, more or less similar to those described after other methods. Some small to medium-sized secretion bodies in the lumen are intensely impregnated by this technique; in general, however, they do not correspond to the sudanophilic and acid hematein-positive bodies. The usual unreliable nature of osmication techniques makes it difficult to interpret the nature of these impregnated elements.

Acid-fast substances. The distribution of the weakly Schiff-positive granules at both ends of the nuclei in the secretory cells suggested the possibility that they might consist of pigments. Therefore, 5 μ paraffin serial sections of material fixed in Zenker-acetic were subjected to staining with Verhoeff's carbol-fuchsin methylene blue for the demonstration of acid-fast material (Lillie, 1948). The granular structures gave a weak, indefinitely pink reaction to this technique also; this cannot be considered a positive reaction as compared with the behavior of certain intensely acid-fast granules in neighboring fat-body cells.

Plate II

All figures are of gelatin-embedded material sectioned on the freezing microtome.

Figure 13. Sudanophilic structures, Level I; sudan black, carmalum. Note scattered globular and vacuolar bodies. 750 ×.

Figure 14. Sudanophilic structures, Level III; sudan black, carmalum. Note scattered vacuole-containing bodies between nucleus and free border. 750 ×.

Figure 15. Acid hematein, Level I. Note masses of formed bodies; scattered stained globules in secretion. 330 ×.

Figure 16. Sudanophilic structures, Level I; sudan black after postchromation. Cf. picture with Figures 13 and 15. 330 ×.

Figure 17. Sudanophilia after postchromation, upper end of transition zone, Level II–III. Cf. abundance and distribution of blackened bodies with that in Figure 16. Note sudanophilic elements in secretion mass. 330 ×.

Figure 18. Portion of same section as in Figure 17, 750 ×. Note concentration of Golgi vacuoles at nuclear caps, progression toward free border.

Figure 19. Acid hematein after pyridine extraction. Cf. Fig. 15. 750 ×.

Figure 20. Acid hematein, Level IV. Note aggregations of vacuole-containing Golgi-bodies at nuclear caps (cf. basophilic areas, Fig. 5). 750 ×.

Figure 21. Acid hematein, transition zone, Level III–IV. Note stained structures at nuclear caps, progression toward free border; deeply-stained bodies in free secretion; large clear areas in secretion mass. 330 ×.

Figure 22. Acid hematein after pyridine extraction, Level III. Cf. Figure 21 for removal of all cytoplasmic stained structures, loss of some staining capacity in free secretion. 330 ×.

PLATE II

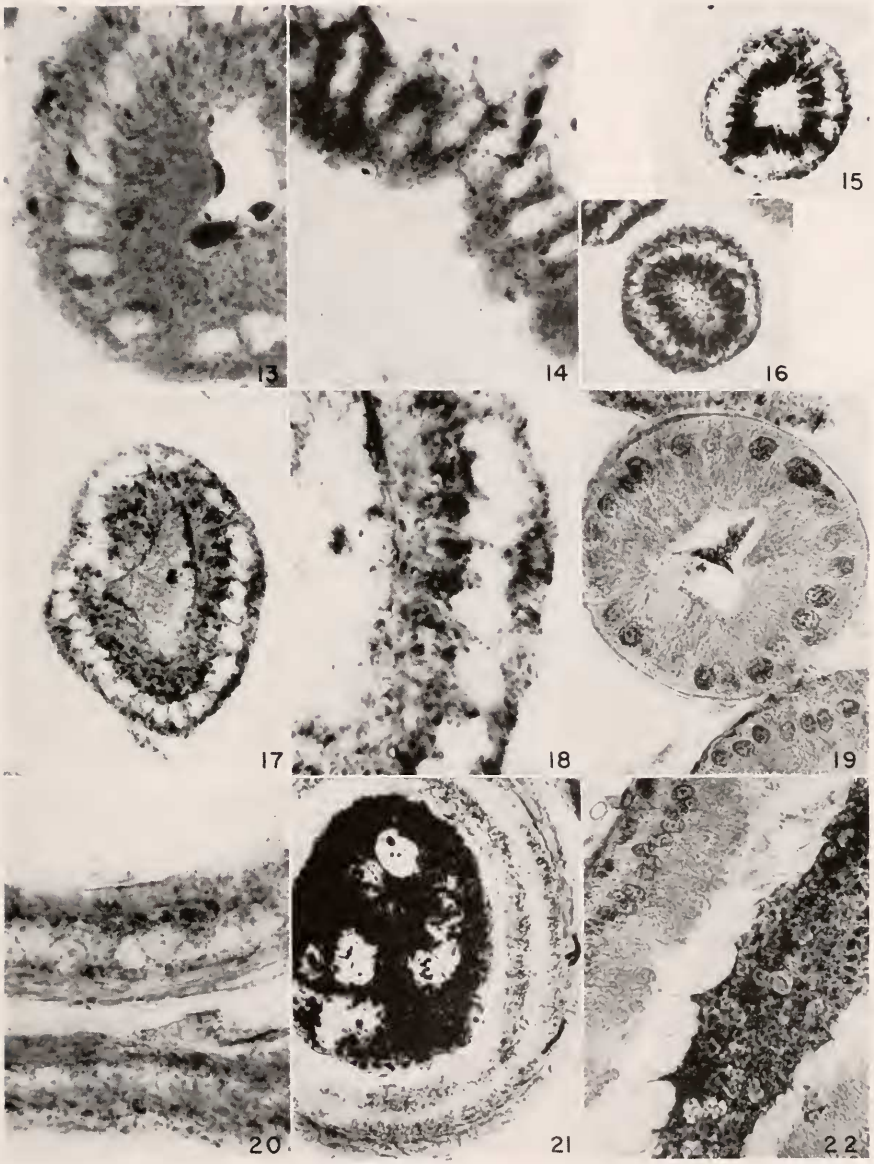

It seems pertinent, at this time, to add a note concerning the appearance of the secretion product in the lumen after various fixatives. The variation in the appearance of the secretion mass following exposure to different fixatives makes it rather difficult to be certain of the correspondence of particular constituents, on the basis of size and appearance, in comparing results of various tests. In general, following treatment with strongly alcoholic fixatives (*e.g.*, Rossman, Zenker), the secretion product appears to consist of a finely-granular ground substance, somewhat shrunken away from the cells of its origin, containing scattered flocculent masses, some small clear vacuoles, and a few larger vacuolar structures. However, after exposure to such comparatively mild fixing fluids as calcium-formaldehyde, the ground substance appears as a mass of small, somewhat hyaline globular structures, bearing scattered larger globules or vacuoles of various sizes; under these conditions the mass shows much less tendency to shrink away from the walls of the gland. This behavior suggests that the ground material and the flocculent masses are composed of substances which tend to imbibe water and to swell, and that the milder fixatives permit this to occur to a certain extent before coagulation supervenes. The rapid action of the strongly alcoholic fixatives precipitates and coagulates the material before imbibition can occur. Alternatively, and perhaps more acceptably, it may be assumed that the normal condition of the secretion in the living animal is more or less similar to that seen after fixation in calcium-formaldehyde, and that this picture is altered by the dehydrating and precipitating action of the stronger fixatives and subsequent treatment of the material with alcoholic fluids.

Discussion

The observations of previous investigators on the histological features of the accessory glands indicate that some similarities exist between the glands of Popillia and those of other more or less closely related beetles. Bordas (1900) described the glands of Lucanus and of Dorcus (family Lucanidae) as composed of a secretory epithelium containing elongate, cylindrical cells, with their protoplasm granular near the base and compact and fibrillar near the free border. These cells release their secretion products by rupture, and globules of this product were frequently seen attached to the cell by a pedicel. Features such as these are characteristic also of the gland of Popillia, but only in the relatively restricted area designated in the present study as Level III.

Rittershaus (1927), working with two members of the same family as that containing Popillia (Anomala and Phyllopertha, fam. Rutelidae), briefly described differences in the type of epithelium present in different regions of their glands. She differentiated between tall, columnar epithelial cells and cuboidal to flattened cells. The lumen of the gland was described by this author as small in the upper region, filled with protoplasmic processes of the epithelial cells; in the lower region, the lumen was said to be clearly expanded and filled with glandular secretion. Rittershaus assumed that the protoplasmic processes were signs of strong secretory activity on the part of the cylindrical cells.

The observations outlined above indicate that regional histological differences in the gland, accompanied by differences in secretory activity, are characteristic also of Popillia. A detailed study of the glands in this species reveals, however, that there are more than the two regions described by Rittershaus. The morpho-

logical differences noted in this study include variations in the diameter of the gland and of its lumen, differences in shape, size, and type of cells, and differences in the amount and nature of the secretion product occupying the lumen. It is apparent that the secretory processes in Levels I and II differ somewhat in characteristics and in type of product from those in Levels III, and that Level IV, as indicated by Rittershaus in other species, serves mainly as an expanded reservoir for the collection and retention of secretions elaborated in the upper regions of the gland.

Cytoplasmic basophilia of the type exhibited in cells of the gland at all levels has been established by numerous investigators, in other materials, as indicating sites of ribonucleoproteins (Brachet, 1940, 1947; Dempsey and Wislocki, 1945, 1946). Intense cytoplasmic basophilia removable by ribonuclease has been reported as characteristic of cells secreting large amounts of protein (Brachet, 1940, and Caspersson *et al.*, 1941, for acinar cells of pancreas; Noback and Montagna, 1947, for salivary gland cells and acinar pancreas cells). In addition, Greenstein (1944) states that cells which synthesize large quantities of protein characteristically have large nucleoli. Noback and Montagna (1947) demonstrated that one or more large nucleoli are present in the nuclei of acinar cells of the pancreas and salivary glands, and that these nucleoli contain ribonucleoprotein. Among others, Brachet (1940) and Dempsey and Wislocki (1945) have also localized ribonucleic acid in cell nucleoli. The present studies have demonstrated the presence of ribonucleoprotein in the cytoplasm and in the large nucleoli of cells of the accessory reproductive glands; this may be considered as an indication that the secretion product of these glands is at least partially protein in nature.

The differences in the shape and distribution of cytoplasmic ribonucleoprotein structures in cells at different levels in the gland are presumably correlated with differences in the secretory activities of the different regions. For example, in the upper levels, where all techniques reveal active secretion, basophilic elements stream from the nuclear membrane to the free border of the cell. In Level IV, however, where cells are evidently not active in secretion, the cytoplasmic nucleoproteins are restricted to a limited and concentrated area surrounding the nuclear caps. These same areas in cells at Level IV also contain lipoid bodies which resemble the Golgi element (vide infra).

Failure to demonstrate appreciable amounts of stored glycogen in cells at any level except the lowest portion of the gland may also be taken as an indication that Level IV is not a secretory region. Other polysaccharides, Schiff-positive after periodic acid but not removed by salivary digestion, are present in accumulations between the nuclei and the free borders of actively secreting cells in the upper levels, but these are present in much smaller amounts in the cells of Level IV. These accumulations lie in cytoplasmic regions which show no affinity for methylene blue; they may be regarded, in view of the apparent polysaccharide nature of the released secretion (see below), as precursors of the secretory products of the cells in which they lie. No regional differences in their cytologic localization are apparent, except their paucity at Level IV.

It is difficult to determine the exact nature of the cytoplasmic structures colored by sudan black without post chromation. However, previous work in germ cells of Popillia has demonstrated that both mitochondria and Golgi-derivatives are re-

vealed by such treatment (unpublished results). The scattered dot-like and vacuole-containing structures shown in cells of the accessory gland by this technique may represent mitochondria and some dispersed and poorly-preserved constituents of the Golgi element. In tissues so treated the cells at any level do not show concentrated juxtanuclear groups of Golgi vacuoles. In thin frozen sections there is a progression of vacuolated sudanophilic structures from the nuclear membrane to the free border, and an apparent increase in size of the vacuoles as they approach the apex of the cell. These things may indicate that these elements are like Golgi-bodies, and they presumably participate actively in secretory processes. Except for their scattered disposition and fewer numbers, they resemble the vacuolated elements demonstrated by sudan black after postchromation; they are like the constituents of the Golgi element described by Cain (1947a) in secretory cells of the alimentary canal of the leech Glossiphonia.

The striking regional differences in the abundance and distribution of lipid elements demonstrated by sudan black after postchromation, and by the acid hematein technique, are conspicuously at variance with the results of simple treatment with sudan black. With these techniques the dense masses of clearly localized droplets and globules shown in Levels I and II have no counterpart in cells at Level III and below. The massive and densely-packed nature of these elements makes it impossible to ascertain the exact morphological nature of the individual bodies. It seems probable, however, that they represent the more or less complete cellular complement of mitochondria and Golgi-bodies, some of which are lost in preparation unless the material is treated with potassium dichromate. The disparity in concentration of these elements between cells in Levels I and II and those in the lower regions of the gland suggests that secretory activity is greater in the upper levels. The appearance of the cytoplasmic phospholipines in these densely-packed cells does not indicate the occurrence of lipophanerosis, as described by Cain (1948) in certain neurones of Helix. This phenomenon was ascribed to a breakdown and release in the cytoplasm of all the cellular phospholipines, resulting in a tendency of the cytoplasm to stain uniformly. In the present instance the cellular phospholipines are not generally distributed, but they are definitely and discretely localized.

The appearance of the free secretion mass indicates that its lipoid components are produced in Levels I and II; these elements first appear in the free secretion in the areas of the gland characterized by an abundance of cytoplasmic phospholipines. It has been noted, (a) that globules of sudanophilic material are found in the secretion in Levels I and II; (b) that sudanophilic droplets lie in a fringe along the borders of cells in Level II, suggesting their having been released at this level; and (c) that certain of the components of the free secretion mass contain phospholipine. The possibility then remains that some of the cellular phospholipine demonstrated in the upper regions of the gland represents a phospholipine-containing product of secretory activity in these cells.

In areas of the gland where cytoplasmic lipoid structures are not obscured by overcrowding, it is clear that the nuclear caps which stain intensely with acid hematein represent the Golgi element as demonstrated by sudan black in postchromed preparations. Using the acid hematein technique, several authors have previously shown that the Golgi-bodies of a variety of tissues contain phospholipine

(Cain, 1947a, for alimentary epithelium of Glossiphonia, and 1948, for nerve cells of Helix; Thomas, 1947, also for nerve cells in Helix; Montagna, Noback, and Zak, 1948, for sebaceous gland cells of man). The present studies show that the Golgi element in cells of the accessory reproductive gland of Popillia also contain phospholipine, along with other lipoid components which cause the vacuolated bodies to color more deeply and more generally with sudan black than with acid hematein.

The presence of the Golgi element within localized cytoplasmic areas which are surrounded by intensely basophilic zones, together with Schiff-positive granules and possibly phospholipine secretion-precursors, suggests that the Golgi-bodies are involved in the elaboration or accumulation of these products.

With regard to the general question of the nature of the secretion product of these glands, it is apparent that it is a mixture of a number of substances, present in the secretion mass as discrete components. Certain of these elements are produced in, and apparently traceable to, particular regions of the long, tubular glands. Within the limits of accuracy of correlating the varying appearances of secretion bodies after various methods of fixation, the following synopsis of their characteristics seems warranted, on the basis of their reactions to the different techniques employed.

1. The ground substance: usually acidophilic; pink reaction with leucofuchsin, not removed by salivary digestion; greenish stain with toluidine blue at pH 3.8, not removed by alcohol; negative reaction with acid hematein test; not sudanophilic. Produced in Levels I and II.

2. Scattered small to medium-sized globules: neither acidophilic nor basophilic; negative reaction to leucofuchsin; no stain with toluidine blue; sudanophilic; positive reaction (at least in part) with acid hematein, negative after pyridine extraction; osmiophilic? Evidently produced in Levels I and II.

3. Scattered larger flocs or globules: basophilic, not affected by ribonuclease; intense purplish stain with leucofuchsin, not removed by salivary digestion; purplish metachromasia with toluidine blue at pH 3.8, unaffected by alcohol or hyaluronidase; sometimes stains with acid hematein, but if so, not removed by pyridine extraction. Produced by apocrine cells in Level III.

On the basis of the characteristics listed, the scattered masses of highly Schiff-positive and metachromatic material described in 3, above, may be interpreted as consisting of mucus. McManus (1946, 1948) has demonstrated that mucus stored in and released from goblet cells in the intestine gives an intense color with leucofuchsin after periodic acid treatment. Wislocki, Bunting, and Dempsey (1947) found that mucus from several sources, including submaxillary glands of the guinea pig, and synovial fluid of rhesus monkeys, gave a strong reaction with the Bauer test. The Wislocki group (1947) found also that mucus gave a characteristically strong purplish metachromasia with toluidine blue, sometimes, but not always (depending on its source) abolished by hyaluronidase. Hempelmann (1940) demonstrated that mucoproteins from various sources, differing chemically, could be distinguished from one another on the basis of metachromatic reactions with toluidine blue and polychrome methylene blue. The secretion of the apocrine cells of the reproductive gland, being metachromatic and Schiff-positive, has the general characteristics of the group of mucoproteins indefinitely termed "mucus."

Other reactions of this material are also significant; in tests of the acid hematein routine using pure substances, Baker (1946) found that mucus occasionally stained, but that the staining reaction was not removed by treatment with pyridine. This is also true of the secretion-masses in the present case, which sometimes give a positive reaction with acid hematein but retain their reactivity after pyridine extraction. In addition, mucus, owing to its acid content, should be expected to show basophilia not removable by ribonuclease; the bodies under discussion show this characteristic.

The granular nature of the intracellular precursors of this secretion product in Popillia, and the evident tendency of the substance to swell upon being released from the cell, are also generally characteristic of mucus. The failure of the precursor-granules to give reactions like those of the released substance is interesting. Baker (1946) in his account of the reactions of various compounds with acid hematein found that, as described above, mucus outside of cells quite often gave a positive reaction, while mucin in the goblet cells of the mouse intestine consistently reacted negatively. Conditions within cells are sufficiently different from those outside cells to make it unreasonable to expect substances to react identically in both situations. However, it would appear that the mucus in the accessory gland secretion differs from the mucus of human jejunal goblet cells, for example, shown by McManus (1948) to be strongly Schiff-positive both before and after its release.

The production of this component of the secretion mass has been ascribed to cells in Level III because it never appears in the lumen above Level III but is characteristically abundant at this level and below.

Since the ground sustance (1, above) which makes up the bulk of the secretion recolors leucofuchsin, it must be related to mucus. That it is not identical with mucus is evident from the fact that its reaction with leucofuchsin is not so intense, and that it never gives a typical purple metachromasia with toluidine blue, but stains green. In addition, it seldom, if ever, reacts with acid hematein, and it is acidophilic. A tendency to stain green with toluidine blue has been reported by Wislocki, Bunting, and Dempsey (1947) for striated muscle fibers, thyroid colloid, stratum lucidum and stratum corneum of epidermis, and occasionally for nuclei. The substance so stained in the present instance would seem to be related in no obvious way to any of the examples cited. One may suggest, on the basis of the appearance of this substance and its reaction with leucofuchsin, that it is related to the mucus produced in Level III. It is probable that both substances are mucoproteins, members of a miscellaneous and widely-distributed group of compounds characterized as protein-polysaccharide complexes differing from one another chiefly in the nature of the polysaccharide moiety and its substituents (Hempelmann, 1940; Meyer, 1945). The periodic-acid-Schiff reaction, as pointed out by McManus (1948), cannot be used to distinguish actual chemical differences within this group of compounds.

The protein nature of secretions in both categories (1 and 3) is inferred from the abundance and intracellular distribution of ribonucleoproteins in cells at Levels I, II, and III, and by the conspicuousness of the ribonucleoprotein-containing nucleoli in cells at these levels.

The third recognizable constituent (2, above) is characterized as either entirely phospholipine or a mixture of phospholipine and other lipoidal substances. The

site of its production has been indicated as Levels I and II; the characteristic droplets or globules of this product first appear in the lumen in these regions of the gland.

On the basis of the results obtained in this study, we may picture the secretion of the accessory reproductive glands as a viscous fluid, composed chiefly of different-sized globules of mucus and mucus-like polysaccharide-protein compounds, containing a certain amount of phospholipine and possibly other lipoids present as scattered droplets. Bordas (1900) described the secretion of these glands in the beetles Lucanus and Dorcus as homogeneous, compact, and "muqueuse," always gelatinous but coagulated by reagents into a hyaline mass. The secretion in Lucanus was described as showing (near the free borders of the cells) the presence of small, refringent globules, some adhering to cells and some free in the lumen. Rittershaus (1927) described and figured the appearance of the secretion mass in Anomala and Phyllopertha as consisting of a finely-granular ground substance containing larger clear bodies; the secretion was described as clumping together in the middle of the lumen and receiving additions of fresh secretion at its perifery.

A secretion product consisting of these components may be considered as admirably adapted to its several functions of lubrication, sperm-suspension, and spermatophore formation.

Summary

1. Differences in secretory activity have been correlated with morphological and cytological regional differences at successive levels in the accessory reproductive glands.

2. Intense cytoplasmic basophilia, abolished by ribonuclease, is characteristic of cells at all levels.

3. The Golgi element of the secretory cells is in the form of vacuolated spherules and is demonstrable by use of sudan black, particularly after postchromation. The Golgi element contains phospholipine.

4. The secretion product of the gland consists of a ground-mass of a mucus-like protein-polysaccharide compound, bearing scattered large globules of mucus and many smaller droplets of phospholipine, and possibly other lipoidal substances.

5. The mucus-like ground substance and the lipoid components are produced in the upper levels of the gland; the mucus globules originate in tall apocrine cells in the middle region; the lower levels apparently do not contribute to the secretion mass but serve as expanded reservoirs for the retention of the finished secretion product.

LITERATURE CITED

Baker, J. R., 1944. The structure and chemical composition of the Golgi element. *Quart. J. Micr. Sci.*, **85**: 1–71.

Baker, J. R., 1946. The histochemical recognition of lipine. *Quart. J. Micr. Sci.*, **87**: 441–470.

Blatter, P. 1897. Étude sur la structure histologique des glandes annexes de l'appareil mâle de l'Hydrophile. *Arch. d'Anat. Micr.*, **1**: 384–416.

Bordas, L., 1900. Recherches sur les organes reproducteurs males des Coléoptères (anatomie comparée, histologie, matière fécondante). *Ann. des Sciences Naturelles*, ser. 8, **11**: 283–448.

Brachet, J., 1940. La detection histochimique des acides pentosenucleiques. *C. R. Soc. Biol.*, **133**: 88–90.

Bracket, J., 1947. Embryologie Chimique. Masson & Cie., Paris.

CAIN, A. J., 1947a. Demonstration of lipine in the Golgi apparatus in gut cells of Glossiphonia. *Quart. J. Micr. Sci.*, **88**: 151–157.

CAIN, A. J., 1947b. An examination of Baker's acid hematein test for phospholipines. *Quart. J. Micr. Sci.*, **88**: 467–478.

CAIN, A. J., 1948. The accumulation of carotenoids in the Golgi apparatus of neurones of Helix, Planorbis, and Limnaea. *Quart. J. Micr. Sci.*, **89**: 421–428.

CASPERSSON, T., H. LANDSTRÖM-HYDEN AND L. AQUILONIUS, 1941. Cytoplasma-nukleotide in Eiweissproduzierenden Drüsenzellen. *Chromosoma*, **2**: 111–131 (not available in original; quoted from Noback and Montagna, 1947).

DEMPSEY, E. W. AND G. B. WISLOCKI, 1945. Histochemical reactions associated with basophilia and acidophilia in the placenta and pituitary gland. *Am. J. Anat.*, **76**: 277–301.

DEMPSEY, E. W. AND G. B. WISLOCKI, 1946. Histochemical contributions to physiology. *Physiol. Rev.*, **26**: 1–27.

DUFOUR, L., 1824. Recherches anatomiques sur les Carabiques et sur plusieurs autres Insectes coléoptères. *Ann. des Sciences Naturelles*, **6**: 150–206.

ESCHERICH, K., 1893. Ueber die verwandtschaftlichen Beziehungen zwischen den Lucaniden und Scarabaeiden. *Wien. Entomol. Zeitung*, **12**: 265–269.

ESCHERICH, K., 1894. Anatomische Studien über das männliche Genital-system der Coleopteren. *Zeit. wissen. Zool.*, **57**: 620–641.

GREENSTEIN, J. P., 1944. Nucleoproteins. Advances in Protein Chemistry. **1**: 210–288. Academic Press, Inc., N. Y.

HEGETSCHWEILER, F., 1820. De Insectorum genitalibus. Inaug. Diss., Turici. (not seen in original; quoted from Escherich).

HEMPELMANN, L. H., JR., 1940. Staining reactions of the mucoproteins. *Anat. Rec.*, **78**: 197–206.

HOTCHKISS, R. D., 1948. A microchemical reaction resulting in the staining of polysaccharide structures in fixed tissue preparations. *Arch. of Biochemistry*, **16**: 131–141.

LILLIE, R. D., 1948. Histopathologic Technic. The Blakiston Co., Philadelphia.

MCMANUS, J. F. A., 1946. The histological demonstration of mucin after periodic acid. *Nature*, **158**: 202.

MCMANUS, J. F. A., 1948. The periodic acid routine applied to the kidney. *Am. J. Pathol.*, **24**: 643–653.

MEYER, K., 1945. Mucoids and glycoproteins. Advances in Protein Chemistry. **2**: 249–275. Academic Press, Inc., N. Y.

MONTAGNA, W., C. R. NOBACK AND F. G. ZAK, 1948. Pigment, lipids, and other substances in the glands of the external auditory meatus of man. *Am. J. Anat.*, **83**: 409–436.

NOBACK, C. R. AND W. MONTAGNA, 1947. Histochemical studies of the basophilia, lipase, and phosphatases in the mammalian pancreas and salivary glands. *Am. J. Anat.*, **81**: 343–367.

RITTERSHAUS, K., 1927. Studien zur Morphologie und Biologie von *Phyllopertha horticola* L. und *Anomala aenea* Geer (Coleopt.). *Zeit. f. wissen. Biol., Abt. A.: Zeit. f. Morph. u. Oekol. der Tiere*, **8**: 271–408.

THOMAS, O. L., 1947. The cytology of the neurones of *Helix aspersa*. *Quart. J. Micr. Sci.*, **88**: 445–462.

WISLOCKI, G. B., H. BUNTING AND E. W. DEMPSEY, 1947. Metachromasia in mammalian tissues and its relationship to mucopolysaccharides. *Amer. J. Anat.*, **81**: 1–37.

WORLEY, L. G., 1946. The Golgi apparatus—an interpretation of its structure and significance. *Ann. N. Y. Acad. Sci.*, **47**: 1–56.